



The Teratogenic Effects of Tartrazine, Food Dye, on the Development of Chick Embryos

Kunlathida Seelarak¹, Vasana Plakornkul², Jantima Roongruangchai³,
Yadaridee Viravud⁴ and Thanaporn Rungruang⁵

¹Master of Science Program in Anatomy – Faculty of Medicine Siriraj Hospital, Mahidol University, kunlathida.s@hotmail.com

²⁻⁵Department of Anatomy – Faculty of Medicine Siriraj Hospital, Mahidol University

ABSTRACT

Tartrazine, a synthetic yellow powder, is used in various components of food and non-food products as well as pharmaceutical products. In addition, the consumption of tartrazine during pregnancy can generate reactive oxygen species which induce embryotoxic and teratogenic effects in the rat fetuses. However, some previous studies have shown that tartrazine does not cause teratogenic potential. This study was to investigate the effects of tartrazine on the development of chick embryos. The 120 white leghorn fertilized eggs were divided into 2 groups: the control group, injected with 0.9% normal saline solution (NSS) and the treated group, injected with tartrazine at 1.0 mg/ml, 1.5 mg/ml and 2.0 mg/ml in 0.9% NSS via the yolk sac. The embryotoxic of tartrazine can cause mortality effect in some embryos. However, the survival embryos were investigated the teratogenic effect of tartrazine using total mount technique. The third day chick embryos showed abnormal formation of heart, limb, eye, and brain with the prominent organ abnormalities including microphthalmia, anophthalmia, and anencephaly. Therefore, tartrazine should be avoided during pregnancy.

Keywords: Tartrazine, Teratogenic Effects, Chick Embryos

1. Introduction

Food dye is substance used in the food products for making attractive and appealing. It is one of the six groups in food additives including food dyes, preservatives, nutritional supplements, flavoring agents, texturing agents and miscellaneous (Güngörmüs et al., 2012). In general, drugs, pesticides and food additives are confirmed to be the teratogenic agents to pregnant women. Teratogens are substances that cause abnormality development of fetus after the exposure during pregnancy (Chung., 2012).

Tartrazine, one of the most azo dye is often used in foods, drugs and cosmetics which is a synthesized lemon yellow color. It can be found in a variety of food such as candies, soft drinks, breakfast cereals, snack foods and desserts (Kobylewski et al., 2010). The acceptable daily intake of 0 - 10 mg/kg body weight is the latest updated by Joint FAO/WHO Expert Committee on Food Additives (Joint et al., 2016) base on the chronic rat study. The toxic effects of tartrazine obtain the reductive biotransformation in the form of an azo bond during metabolism.



Breaking down of an azo bond to low molecular aromatic amine is very harmful to the living organism because the toxic metabolites lead to the increase of mitochondrial permeability (Cemek et al., 2014). The previous study demonstrated that tartrazine have a significant toxic effect by increase the level of oxidative stress and decrease the level of antioxidant (Amraoui et al., 2018). Additionally, high doses of tartrazine caused disturbance in fertility capacity (Khayyat et al., 2017). Recent study by Hashem et al (2019) reported that tartrazine have embryotoxicity and teratogenicity in rat fetuses but no teratogenic effect in humans.

Therefore, this study is interested in the teratogenic effects in tartrazine on the chick embryos. This animal model is selected because of its simplicity, short gestation, easily manipulated in the experiment and similarity to human embryos.

2. Objectives of the study

The purposes of this study were to investigate the teratogenic effects of tartrazine on the third day chick embryo: abnormality and retardation development by using total mount technique.

3. Materials and methods

Chemical: Tartrazine powder was purchased from chemical store in Thailand.

Animal model: The white leghorn hen fertilized eggs (*Gallus domesticus*) were obtained from Suwanvajok kasikit research station, Department of Animal Sciences, Faculty of Agriculture, Kasetsart University in Thailand.

The 120 fertilized eggs were randomly divided into 2 groups; the control group and the experimental group which were divided 30 eggs in each group. All eggs were incubated at 37 ± 0.5 °C and 70-80% humidity. After 24 hours of incubation, the eggs were removed from incubator and cleaned at the blunt ends of eggshell with 70% ethyl alcohol. The blunt end of eggs will be drilled to get a small hole for injection with sterile needle to the yolk sac in each group through a small hole. In the control group, the fertilized eggs were injected 0.1 ml of 0.9% NSS whereas the treated group was randomly subdivided into 3 groups and were injected 0.1 ml of the different concentrations of tartrazine at 1.0 mg/ml, 1.5 mg/ml and 2.0 mg/ml in NSS which were randomly determined by preliminary study for LD₅₀ of chick embryos. After sealing the hole with adhesive tape, the fertilized eggs were re-incubated. On the third embryonic day, these fertilized eggs were opened and recorded the survival and mortality rates.

Experimental method for the total mount technique: The survived chick embryos in all groups were collected and fixed in Dietrich's FAA solution for 4 hours. Then they were transferred to 70% ethyl alcohol, cut to the round shaped and put in the cassettes. After that, the specimens were processed in distilled water, Mayer's staining, dehydration, clearing and mounting, respectively. The mounting embryonic specimens were observed the morphological abnormalities.



4. Results

The survival and mortality rates of the third day chick embryos were determined by the heart beating and blood circulation which were compared to the third day normal chick embryos (the fourth week of human embryos). The survival rate and mortality rate of third day chick embryo were shown in **Table 1**.

Table 1 The percentage of the survival and mortality rate of third day chick embryos.

Group	Survival rate n (%)	Mortality rate n (%)
Control group (n = 30)	30 (100.00)	0 (0.00)
Tartrazine at 1.0 mg/ml (n = 30)	22 (73.33)	8 (26.67)
Tartrazine at 1.5 mg/ml (n = 30)	15 (50.00)	15 (50.00)
Tartrazine at 2.0 mg/ml (n = 30)	12 (40.00)	18 (60.00)
Total (N = 120)	79 (65.83)	41 (34.17)

Table 1 showed that the percentage of the mortality rate in the experimental groups resulted increased with high concentration, tartrazine at 1.0 mg/ml, 1.5 mg/ml and 2.0 mg/ml were 26.67%, 50%, and 60%, respectively compare to the control group.

The total mount of the third day chick embryos

In the control group of the third day chick embryos in **Figure 1 A** showed normal development as the stage 18 (Hamburger et al., 1992), the longitudinal axis rotated 2/3 at the cephalic part and twisted 90° turned the face to the right side and presented 2 flexures consist of the cephalic flexure which located at mesencephalon and the cervical flexure located between myelencephalon and spinal cord. The 5 parts of secondary brain vesicle were developed from the 3 parts of primary brain vesicle including the forebrain were telencephalon and diencephalon, the midbrain was mesencephalon and the hindbrain were metencephalon and myelencephalon. The heart looping turned to the ventral of the body as S-shaped. The 4 pairs of branchial arches were completely developed. The vesicle of otocyst was closed and located at myelencephalon. The optic cup and the lens vesicle located at diencephalon. The neural tube appeared 2 parallel dense lines which extended to the caudal end. The 36 pairs of somites extended from the cervical flexure to the caudal end. The anterior limb buds, the posterior limb bud and the tail fold were distincted.



The experimental groups of tartrazine showed the abnormality of several structures when compared to control group. The 1.0 mg/ml in **Figure 1 B**, the brain vesicles and the flexures of cephalic flexure and cervical flexure were retarded development. The heart looping was dilated as U-shaped. The limb buds and the tail fold were absent. Somites retardation appeared only $\frac{3}{4}$ of the body. The 1.5 mg/ml in **Figure 1 C**, the retardation of brain vesicles and the flexures were more severe than the 1.0 mg/ml which can hardly recognized the 3 parts of the primary brain vesicle. The both eyes were abnormally small as microphthalmia. The heart looping was abnormally collapsed. Somites retardation appeared only $\frac{3}{4}$ of the body and the 2.0 mg/ml in **Figure 1 D**, the anterior neuropore was still opened, leading to anencephaly. The both eyes were absent as anophthalmia. The branchial arches were absent. The heart looping was abnormally collapsed. The limb buds were absent. Somites retardation appeared only $\frac{3}{4}$ of the body.

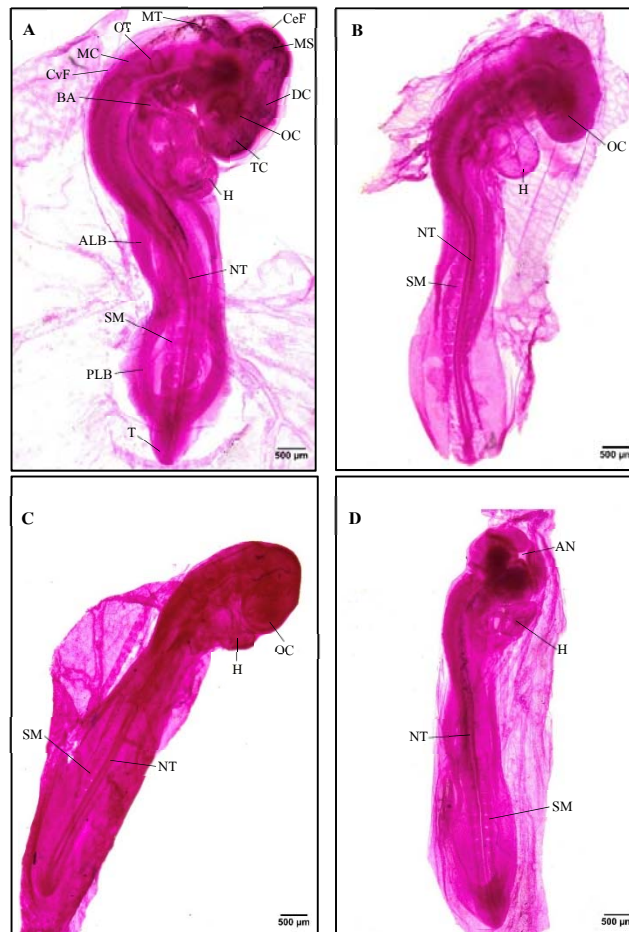


Figure 1 The total mount of the third day chick embryos, A. control group, B. 1.0 mg/ml of tartrazine, C. 1.5 mg/ml of tartrazine and D. 2.0 mg/ml of tartrazine. (TC: Telencephalon, DC: Diencephalon, MS: Mesencephalon, MT: Metencephalon, MC: Myelencephalon, CeF: Cephalic flexure, CvF: Cervical flexure, H: heart, OC: Optic cup, OT: Otocyst, BA: Branchial arch, ALB: Anterior limb buds, PLB: Posterior limb buds, NT: Neural tube, SM: Somite, T: Tail fold, AN: Anterior neuropore).



5. Discussion

This study revealed that tartrazine, food dye, were observed in the eye caused microphthalmia and anophthalmia as well as the brain caused anencephaly in the third day of early chick embryos is teratogenic effects.

The teratogenic effect of tartrazine showed microphthalmia in middle concentration, 1.5 mg/ml of tartrazine. The result corresponding with Joshi et al (2019) reported sunset yellow, food dye in high concentration, 40 mM showed microphthalmia in 72 hours of zebrafish embryos.

High concentration, 2.0 mg/ml of tartrazine showed anencephaly and anophthalmia. There was no report of the abnormalities of anencephaly and anophthalmia in this concentration. However, other substances or chemicals such as food additives were reported about teratogenic effects. The anterior neuropore was opened, leading to anencephaly. In Ovalioglu et al., 2020 showed erythrosine, food dye in concentrations 0.05 mg/kg and 0.1 mg/kg increased the neural tube defects in 72 hours of early chick embryos and corresponding with Monis et al (1981) lambda-carrageenan, food additive, induced anencephaly in the chick embryos. Colson et al (1984) have been studied Saccharin, food additive, presented the anophthalmia in rat embryos.

Tartrazine indicated that oxidative stress in the free radical forms induced the brain tissue damages of apoptosis (Gao et al., 2011). Therefore, it caused increase of the mortality rates, growth retardation and abnormalities in the chick embryos. This study is useful for pregnant women to be aware of tartrazine consumption to avoid the fetal abnormality development.

6. Conclusion

The effects of tartrazine, food dye, in the third day of chick embryos could induce the abnormality development. This caution is for pregnant woman who consumes the food contaminated with tartrazine that this substance can pass placenta to embryo. This study was the first found that tartrazine can induced the eye defects in chick embryos. Further study, the teratogenic effects of tartrazine could investigate more specific study in the eye defects.

Acknowledgements

This study was supported by my advisor, co-advisor as well as the CIOTS's center at Department of Anatomy, Faculty of Medicine Siriraj Hospital, Mahidol University.

References

- Amraoui, W., Adjabi, N., Bououza, F., Boumendjel, M., Taibi, F., Boumendjel, A., Messarah, M. (2018). Modulatory Role of Selenium and Vitamin E, Natural Antioxidants, against Bisphenol A-Induced Oxidative Stress in Wistar Albinos Rats. *Toxicol Res*, 34(3), 231-239. doi:10.5487/TR.2018.34.3.231



- Cemek, M., Emin Büyükkuroglu, M., Sertkaya, F., Alpdağtas, S., Hazini, A., Öñül, A., & Gönes, S. (2014). Effects of Food Color Additives on Antioxidant Functions and Bioelement Contents of Liver, Kidney and Brain Tissues in Rats. *Journal of Food and Nutrition Research*, 2(10), 686-691. doi:10.12691/jfnr-2-10-6
- Chung, W. (2012). Teratogens and their effects. *The New Public Health: An Introduction for the 21st Century*.
- Colson, A., Lederer, J., & Michiels, J. (1984). Ocular lesions induced by saccharin and its pollutants in the rat fetus. *Journal Français d'Ophtalmologie*, 7(5), 399-410.
- Gao, Y., Li, C., Shen, J., Yin, H., An, X., & Jin, H. (2011). Effect of Food Azo Dye Tartrazine on Learning and Memory Functions in Mice and Rats, and the Possible Mechanisms Involved. *Journal of Food Science*, 76, T125-129. doi:10.1111/j.1750-3841.2011.02267.x
- Güngörmüş, C., & Kılıç, A. (2012). The safety assessment of food additives by reproductive and developmental toxicity studies. *Food Additive, InTech*, 31-48.
- Hamburger, V., & Hamilton, H. L. (1992). A series of normal stages in the development of the chick embryo. *Developmental Dynamics*, 195(4), 231-272.
- Hashem, M. M., Abd-Elhakim, Y. M., Abo-El-Sooud, K., & Eleiwa, M. M. E. (2019). Embryotoxic and Teratogenic Effects of Tartrazine in Rats. *Toxicol Res*, 35(1), 75-81. doi:10.5487/TR.2019.35.1.075
- Joint, F., Organization, W. H., & Additives, W. E. C. o. F. (2016). Evaluation of certain food additives: eighty-second report of the Joint FAO. *WHO Technical Report Series; 1000*.
- Joshi, V., & Pancharatna, K. (2019). Food colorant Sunset Yellow (E110) intervenes developmental profile of zebrafish (*Danio rerio*). *Journal of Applied Toxicology*, 39(4), 571-581. doi:10.1002/jat.3747
- Khayyat, L., Essawy, A., Sorour, J., & Soffar, A. (2017). Tartrazine induces structural and functional aberrations and genotoxic effects in vivo. *PeerJ*, 5, e3041. doi:10.7717/peerj.3041
- Kobylewski, S., & Jacobson, M. F. (2010). *Food dyes: A rainbow of risks: Center for Science in the Public Interest*.
- Monis, B., & Rovasio, R. A. (1981). Teratogenic effect of lambda carrageenan on the chick embryo. *Teratology*, 23(2), 273-278.
- Ovalioglu, A. O., Ovalioglu, T. C., Arslan, S., Canaz, G., Aydın, A. E., Sar, M., & Emel, E. (2020). Effects of Erythrosine on Neural Tube Development in Early Chicken Embryos. *World Neurosurgery*, 134, 822-825. doi:10.1016/j.wneu.2019.11. 017